

## Eş zamanlı prostat ve böbrek kanseri: İki olguluk seri

*Synchronous prostate and renal cancer: A series of two cases*

Fatih Akdemir<sup>1</sup>, Önder Kayıgil<sup>2</sup>, Emrah Okulu<sup>3</sup>

<sup>1</sup> Samsun Terme Devlet Hastanesi Üroloji Uzmanı, Samsun

<sup>2</sup> Yıldırım Beyazıt Üniversitesi Tıp Fakültesi, Üroloji Ana Bilim Dalı, Ankara

<sup>3</sup> Ankara Atatürk Eğitim ve Araştırma Hastanesi, Üroloji Kliniği, Ankara

*Geliş tarihi (Submitted): 07.08.2017*

*Kabul tarihi (Accepted): 01.10.2017*

### Yazışma / Correspondence

Fatih Akdemir

Gölevi Mahallesi, Toki Sokak, No:

11/21, Ünye, Ordu, Türkiye

Phone: 0538 404 0494

E-mail: nfatihakdemir@hotmail.com

### Özet

Genitoüriner sistemde eş zamanlı olarak prostat ve böbrek tümörlerinin görülmesi nadir bir durumdur. Yaşam süresindeki uzama ve tanı yöntemlerindeki gelişmelere paralel olarak primer multipl senkronöz tümör görülme oranında artış beklenebilir. Biz prostat ve böbrek kanserinin nadir olarak birlikte görüldüğü, iki olguyu literatürde gözden geçirerek sunduk.

**Anahtar Kelimeler:** Eş zamanlı tümör, Prostat adenokarsinomu, Renal hücreli Karsinom

### Abstract

Synchronous prostate and renal cancer is rarely encountered in the genitourinary system. An increase in the incidence rate of multiple synchronous tumors can be expected in parallel to the prolongation of time of life and the developments in diagnostic methods. The present study aimed at reporting two cases with a rarely seen association of prostate and renal cancer while reviewing the literature.

**Keywords:** Synchronous tumor, Prostate adenocarcinoma, Renal cell carcinoma

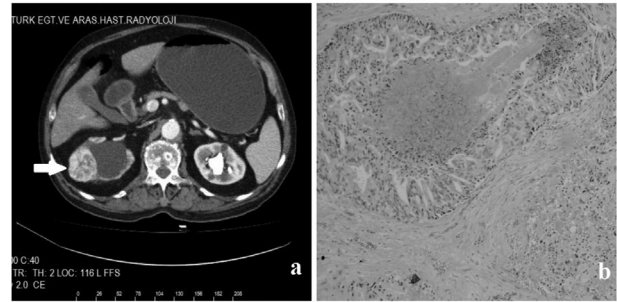
## INTRODUCTION

Two different tumors detected in one organ simultaneously or primary tumors seen in two different organs are referred to as synchronous tumors. If the second tumor develops after more than 12 months, they are referred to as metachronous tumors<sup>(1)</sup>. Association of prostate and renal carcinoma is a rarely seen situation. Primary malignant tumors seen synchronously with renal cancer are bladder cancer, prostate cancer, colorectal cancer, lung cancer, malignant melanoma, and nonHodgkin lymphoma<sup>(2)</sup>. While patients with malignancies are scanned for metastasis, the presence of a synchronous primary tumor should not be forgotten. The objective of the present study was to probe into two cases with synchronous acinar type prostatic adenocarcinoma and renal cell carcinoma.

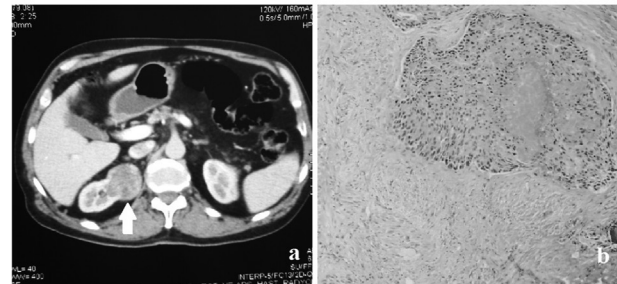
## CASE REPORT

**CASE 1:** Upon detecting, during routine checks, that PSA of a 69-year-old male patient was 50 ng/dl, transrectal ultrasonography-guided prostate biopsy was performed. As a result of histopathological evaluation, Gleason 5+4 acinar type prostate adenocarcinoma was detected (Figure 1a). In the wake of abdominal CT, a mass with a 4 cm diameter compatible with renal cell carcinoma was observed in the right kidney (Figure 1b). In whole body bone scintigraphy, a metastatic center was detected in the left scapula. Maximal androgen blockade for prostatic adenocarcinoma was initiated and right partial nephrectomy was performed for renal mass in the patient with good general condition and no additional comorbidities. As a result of the pathologic examination of the excised mass, the mass was reported to be the clear cell variant of renal cell carcinoma. No relapse was seen dependent on the renal cell carcinoma in the follow-ups of the patient.

**CASE 2:** A 62-year-old male patient was undergoing a routine check when a mass was detected in his right kidney by ultrasonography. An abdominal CT was performed thereafter and a mass, about 5 cm in diameter, compatible with renal cell carcinoma was observed in the medial part of the right kidney (Figure 2a). The patient's PSA value measured approximately 7 months before operation was found to be 6.5 and decreased to 3.7 after treatment with chronic prostatitis. After having carried out necessary preparations, right radical nephrectomy was performed with right chevron incision. As a result of the pathologic evaluation of the



**Figure 1:** a: RCC-concordant mass seen in the lateral part of the right kidney b: Histopathological image of the prostate adenocarcinoma (H+EX200).



**Figure 2:** a: RCC-concordant mass seen in the medial part of the right kidney b: Histopathological image of the prostate adenocarcinoma (H+EX200)

mass, the mass was reported as clear cell subtype of renal cell carcinoma. During the third month follow-up of the patient, his PSA was detected as 15,8 ng/dl. The patient underwent prostate biopsy in the presence of transrectal ultrasonography. As a result of the histopathological examination was reported as Gleason 4+5 acinar prostatic adenocarcinoma (Figure 2b). In whole body bone scintigraphy, a metastatic center was not detected. The general condition and the 10 year life expectancy were evaluated as positive. After having finished necessary preparations, retropubic radical prostatectomy was performed on the patient. The pathologic evaluation of the prostate reported Gleason 4+5 acinar type prostatic adenocarcinoma. Subsequently the patient was treated with radiotherapy.

## DISCUSSION

Cases of primary multiple malignancies comprise 1.84% of all malignant cases<sup>(3)</sup>. Theodore Bilroth reported a case of a multiple, primary, synchronous malignancy in the same patient for the first time in 1889<sup>(4)</sup>. The prevalence of synchronous cancer in cases with urologic cancer fluctuates between 2.8% and 6.3%<sup>(5)</sup>. Osman et al. have reported that the risk of incidence of a second tumor in patients with a

urologic malignancy increases 1.11% every month<sup>(6)</sup>.

Warren and Gates have described the widely accepted form of synchronous tumors. Accordingly, each and every tumor must be malignant, they should be different histologically, and the possibility of metastasis must be ruled out<sup>(7)</sup>. Synchronous tumors have been shown to increase depending on too much radiation as a result of the radiologic methods used during diagnosis and follow-up of the disease or chemotherapeutics<sup>(7)</sup>. Family history and syndromes, diseases causing immunosuppression, improved diagnostic methods, success in cancer treatment, increased elderly population, and life expectancy are factors related to the increase in the incidence of multiple synchronous primary cancer<sup>(8)</sup>. Moreover, advanced age and genetic factors have also been shown to be strongly related to multiple primary malignancies<sup>(9)</sup>. In a study conducted by Heidegger I and colleagues, 51.3% of incidental prostate carcinomas were detected in a series containing 213 cases of radical cystoprostatectomy<sup>(10)</sup>. In a multicenter study involving 4299 patients, the incidence of prostate carcinoma in radical prostatectomy specimens was 21.7%.<sup>(11)</sup> It can also be said that this association may be metachronous tumors, especially due to the incidence of prostate cancer increasing with age. In another study, 4.1% had multiple urological cancers as a result of the evaluation of 2440 urological cancer patients. Only 8 cases of prostate and renal cancer have been reported in these patients<sup>(12)</sup>.

Other multiple tumors accompanying primary renal tumor belong to the genitourinary system (kidney, bladder, prostate) and the hematopoietic system (Hodgkin lymphoma, multiple myelomas, chronic lymphocytic leukemia). When there is a primary neoplasia in the kidney, the reason why another secondary neoplasia develops has been interpreted as the development of a de novo neoplasia of the kidney and the addition of a metastatic tumor on a renal tumor<sup>(13)</sup>. Synchronous tumors can develop in the same organ in different histologic types, and also can be seen synchronously in other organs, as it was seen in our case.

A comparison can be made with the publishing of reports regarding multiple primary synchronous neoplasia, and risk factors regarding the development of synchronous and metachronous tumors can be designated. Hence, survival time can possibly be prolonged by minimalizing environmental and patient-related risk factors and early diagnosis and treatment can be made. Moreover, genetic research on these patients can be taken much further. Thus, keeping in mind the fact that other synchronous tumors can be pres-

ent together with the probability of metastasis in tumoral formations in multiple organs and conducting diagnostic procedures are of grave importance.

## REFERENCES

1. Oncel M, Kurt N, Altuntaş YE, et al. A patient with metachronous gastric, colonic and thyroid cancers: A case report. *Int Surg* 2003;88:1-5.
2. Demirkol MK, Faydacı G, Çelik O, et al. Synchronous Bladder, Prostate and Bilateral Kidney Tumors: A Case Report. *J Kartal TR* 2013;24:122-5.
3. Balat O, Kudelka AP, Ro JY, et al. Two synchronous primary tumors of the ovary and kidney: a case report. *Eur J Gynaecol Oncol* 1996;17:257-9.
4. Billroth T. 51 Vorlesungen: A Textbook for Students and Physicians in Fifty-one Lectures. 14th ed. Berlin: G. Reimer; 1889. General surgical pathology and therapeutics; p. 908.
5. Smith MT, Taylor FD, Gianakopoulos WP, Brown RR. Two Separate Synchronous Primary Genitourinary Tumors. *Rev Urol* 2012;14:104-7.
6. Osman I, Kaya E, Alagol B, et al. Multiple primary malignant neoplasms in urologic patients. *Int Urol Nephrol* 2004;36:1-4.
7. Warren S, Gates O. Multiple primary malignant tumors: a survey of the literature and a statistical study. *Am J Cancer* 1932;16:1358-1403.
8. Sonneveld P, Kurth KH, Hagemeyer A, Abels J. Secondary hematologic neoplasm after intravesical chemotherapy for superficial bladder carcinoma. *Cancer* 1990;65:23-5.
9. Haraguchi S, Koizumi K, Hioki M, et al. Hereditary factors in multiple primary malignancies associated with lung cancer. *Surg Today* 2007;37:375-8.
10. Heidegger I, Oberaigner W, Horninger W et al. High incidence of clinically significant concomitant prostate cancer in patients undergoing radical cystectomy for bladder cancer: A 10-year single-center experience. *Urol Oncol* 2017;35:152.
11. Pignot G, Salomon L, Neuzillet Y et al. Clinicopathological characteristics of incidental prostate cancer discovered from radical cystoprostatectomy specimen: a multicenter French study. *Ann Surg Oncol* 2014;21:684-90.
12. Chirila DN, Turdeanu NA, Constantea NA et al. Multiple malignant tumors. *Chirurgia (Bucur)* 2013;108:498-502.
13. Lynch HT, Harris RE, Lych PM, et al. Role of heredity in multiple primary cancer. *Cancer* 1977;40:1849-1854.